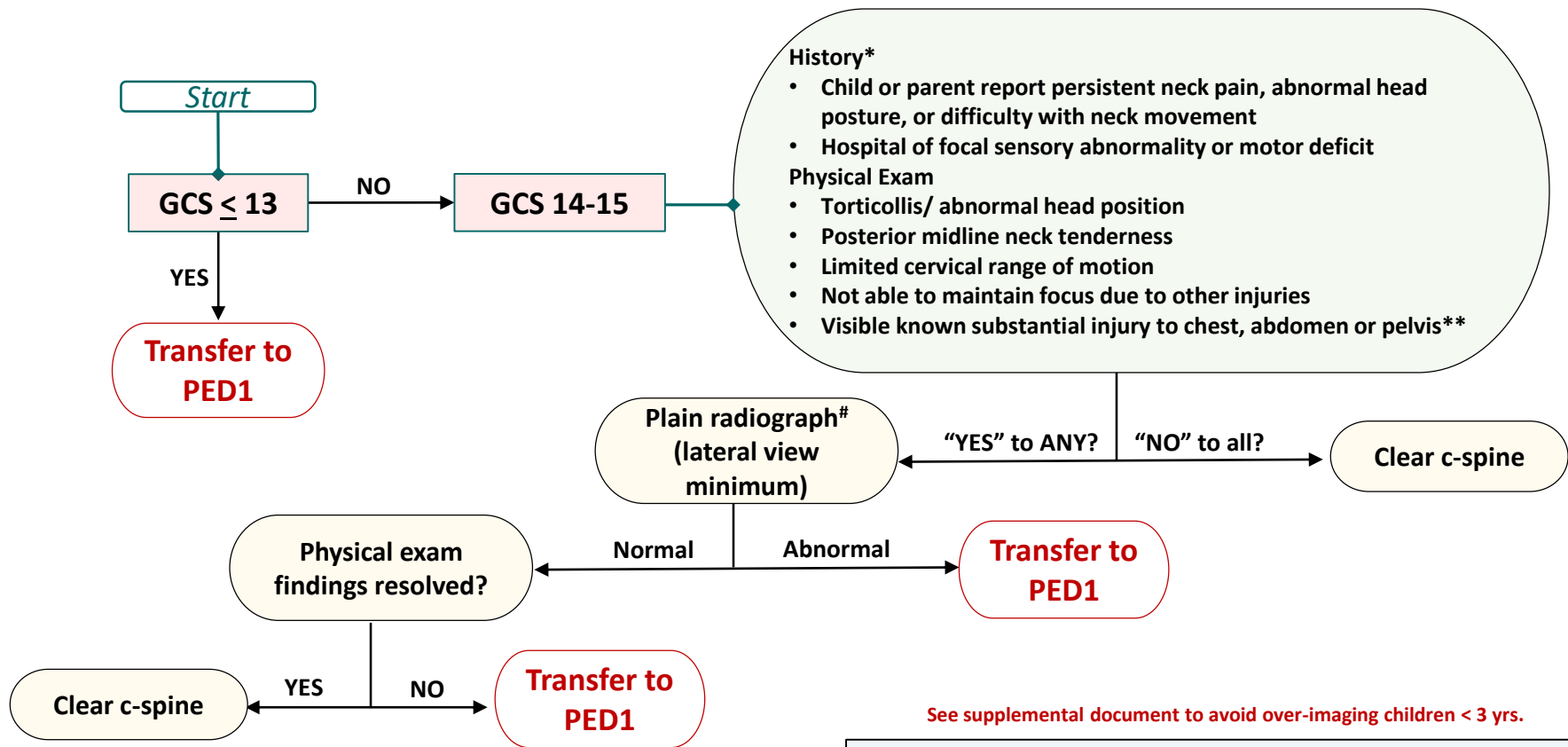


2022 Pediatric Cervical Spine Clinical Guideline

Blunt Mechanism



See supplemental document to avoid over-imaging children < 3 yrs.

*Stronger consideration for imaging should be given toward patients with the following mechanisms of injury: diving, axial load, clothes-lining and high risk MVC (head-on collision, rollover, ejected from the vehicle, death in the same crash, or speed > 55 mph)

** Substantial injury is defined as an observable injury that is life-threatening, warrants surgical intervention or warrants inpatient observation

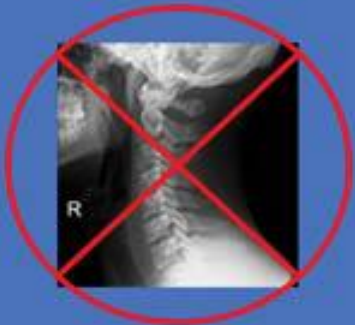All imaging should be read by an attending physician

This algorithm does not replace clinical judgment and is not intended to be prescriptive for all patients.

C-Spine Clearance: Who Doesn't Need Imaging?

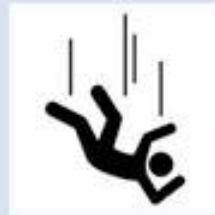No Imaging Needed

- GCS 14 or 15
- Not intoxicated
- < 3 years & no high-risk mechanism*



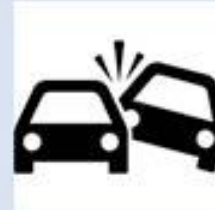- No neurologic deficit
- No midline tenderness
- No distracting injuries
- No unexplained hypotension

*Exceptions Based on Mechanism (<3 years)



Fall > 10 feet

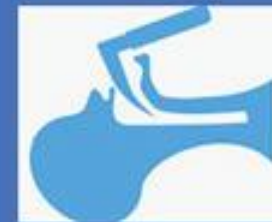Motor Vehicle Collision



Non-Accidental Trauma

Special Populations

- Persistent pain & normal x-rays
- Advanced imaging vs. c-collar?



- Obtunded or intubated & normal CT
- Risk of pressure sore w/c-collar
- MRI or remove c-collar?

AVOID over-imaging for c-spine clearance



APSA
American Pediatric
Surgical Association
Saving Lifetimes

APSA EDUCATION COMMITTEE

#APSA Learning



Pediatric Cervical Spine Clearance Recommendations



Step 1



IS IMAGING NEEDED?
EVALUATE FOR:

Symptoms:

- Neck pain, difficulty w/ movement
- Focal sensory/motor deficit

Mechanism:

- Dive/axial load, clothesline
- MVC w/ any of: rollover, head-on, death of other, >55mph

Physical Exam:

- GCS < 14
- Torticollis or limited motion
- Midline injury
- Distracting injury
- Substantial injury to torso on admission

If any present - go to Step 2

Step 2



IF ANY PRESENT
ASK FOR:

Lateral C Spine X-ray if:

GCS 14+
OR

GCS 9-13 anticipated to improve to 14+ within 24 hs



Non-con C spine CT if:

GCS < 9
OR

GCS 9-13 unlikely to improve in 24 hs



Step 3

NEXT STEPS:

ABNORMAL X-Ray: Consult spine

Normal X-Ray +

- No other symptoms: **clear clinically**
- Midline neck pain:
 - Maintain collar 2 wks and repeat exam
 - Flex-ex with at least 30 degrees
 - **Consult spine**

ABNORMAL CT: Consult spine

NORMAL CT +

- Anticipate GCS 14+ w/in 72 hrs → repeat exam:
 - Exam normal: **clear clinically**
 - **Exam abnormal: consult spine**
- Unlikely to be GCS 14+ w/in 72h → **MRI**



ABNORMAL MRI: Consult spine

NORMAL MRI: Clear C-spine



@StayCurrentMD

Created by
Cecilia Gigena, MD
@gigenace

Adapted from: **Herman, Martin J. MD**

Orthopedic Center for Children, St. Christopher's Hospital for Children, Philadelphia, Pennsylvania

doi: 10.2106/JBJS.18.00217

@PediTraumaSoc

@APSASurgeons

Pediatric Trauma Society
A Voice for the Injured Child

